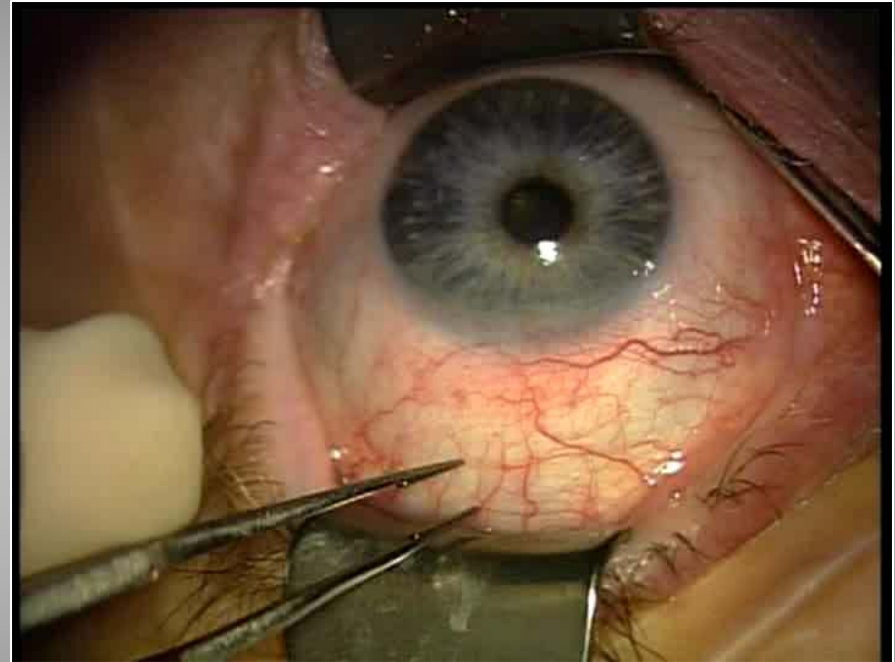


Surgical Procedures for Conjunctivochalasis

For Inf. CCh:

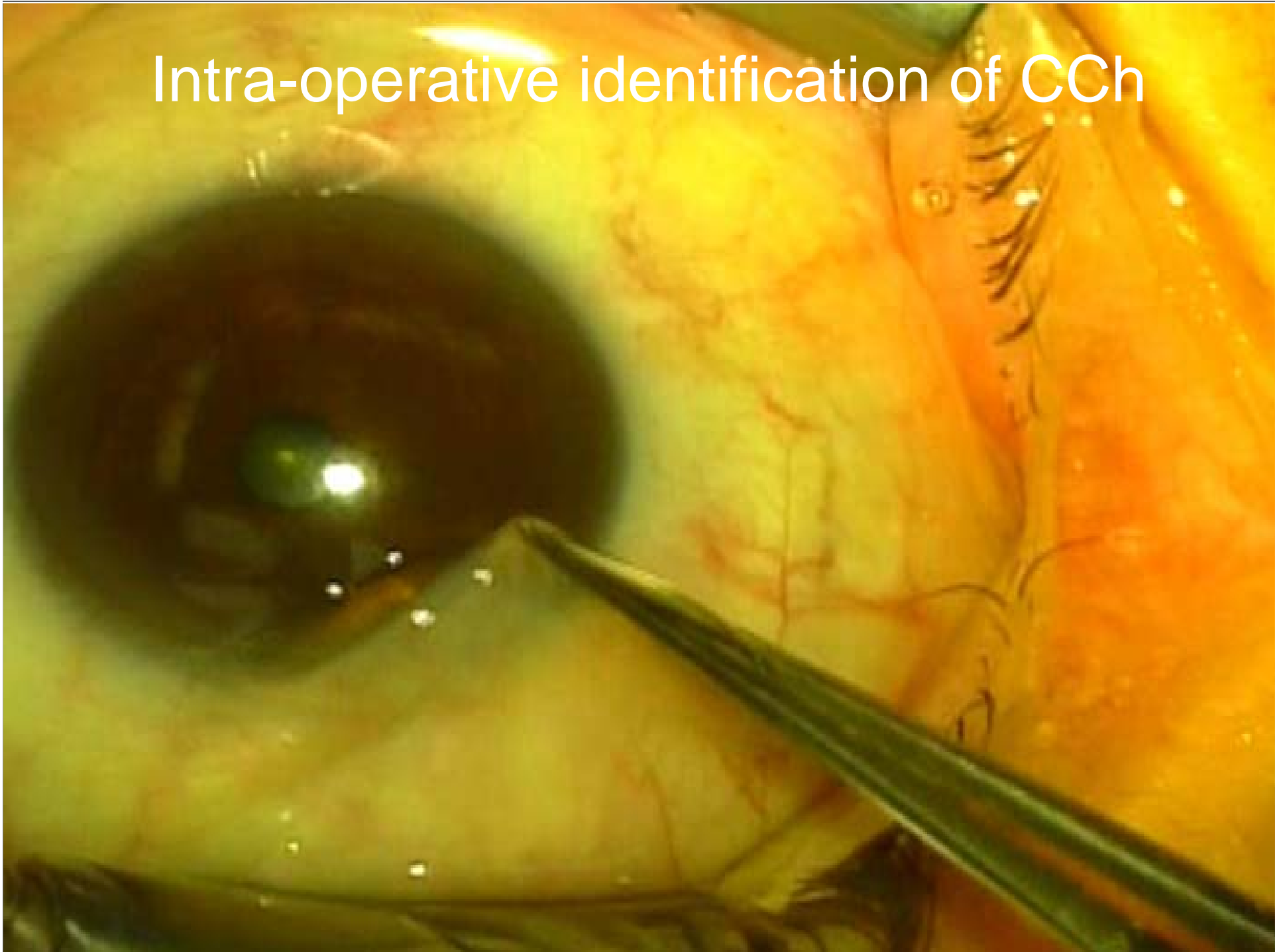
- Topical anesthesia with 1:1000 epinephrine and 2% lidocaine
- Identification of Loose Conjunctiva
- Inferior peritomy at the limbus
- 7-0 Vicryl Traction suture at 6:00
- Excise coexisting **pinguecula**
- Excise loose conjunctiva 3 to 4 mm
- Anchor conjunctiva to the fornix with 7-0 Vicryl mattress sutures to prevent **fat prolapse**
- AM with fibrin glue



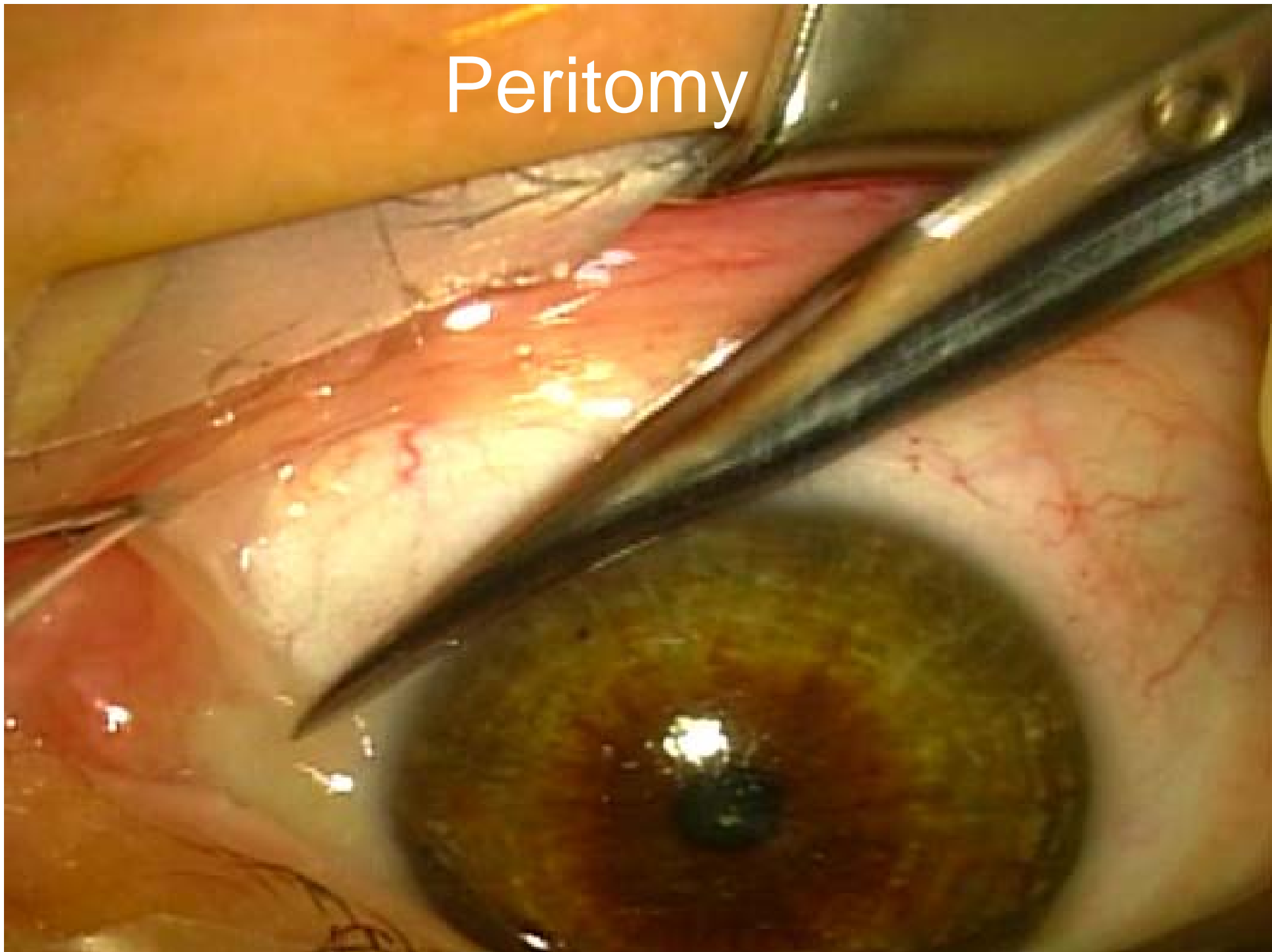
For SLK/Sup. CCh:

Tenon's Capsule Replacement
and Reinforcement by AM

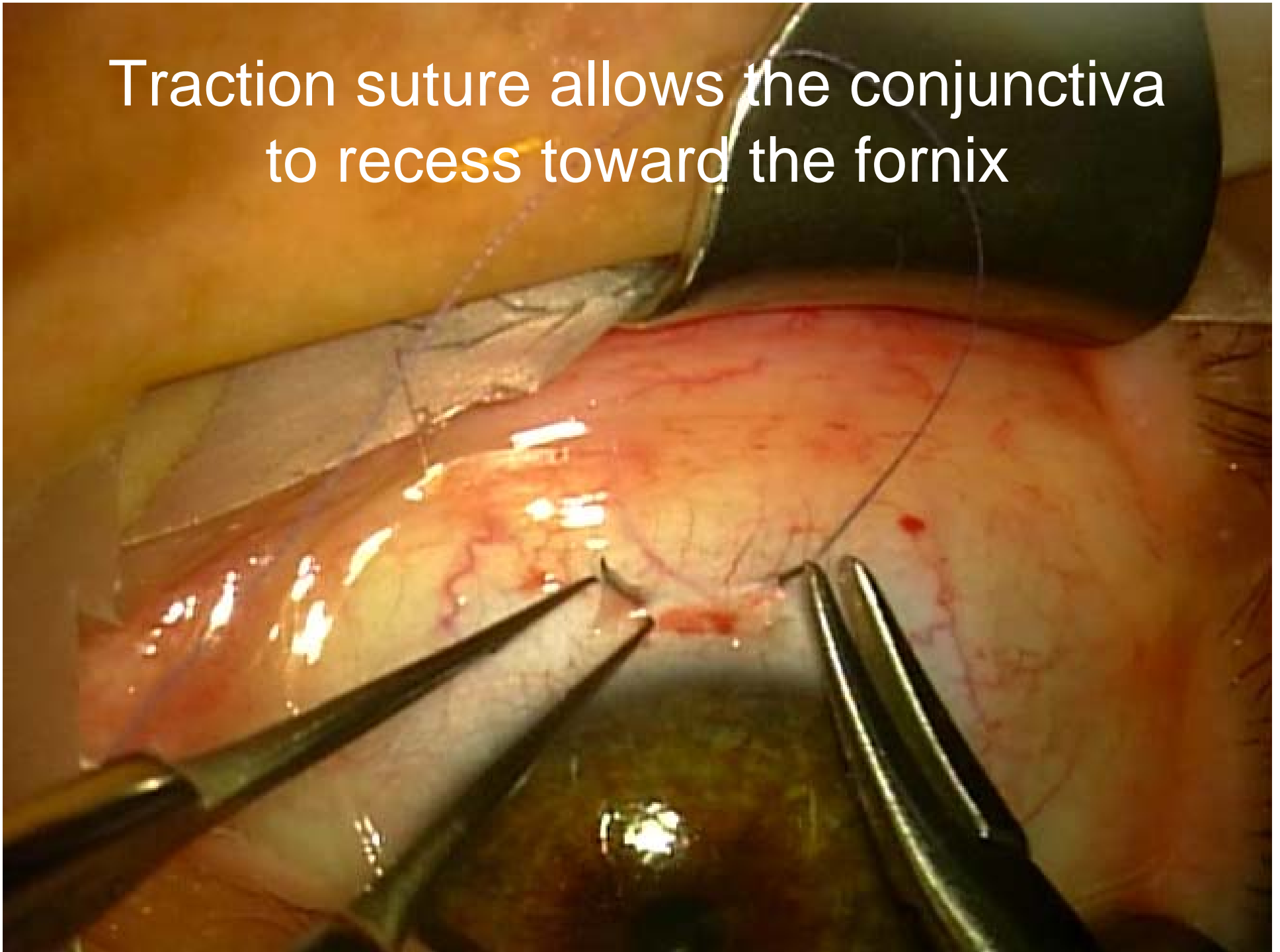
Intra-operative identification of CCh



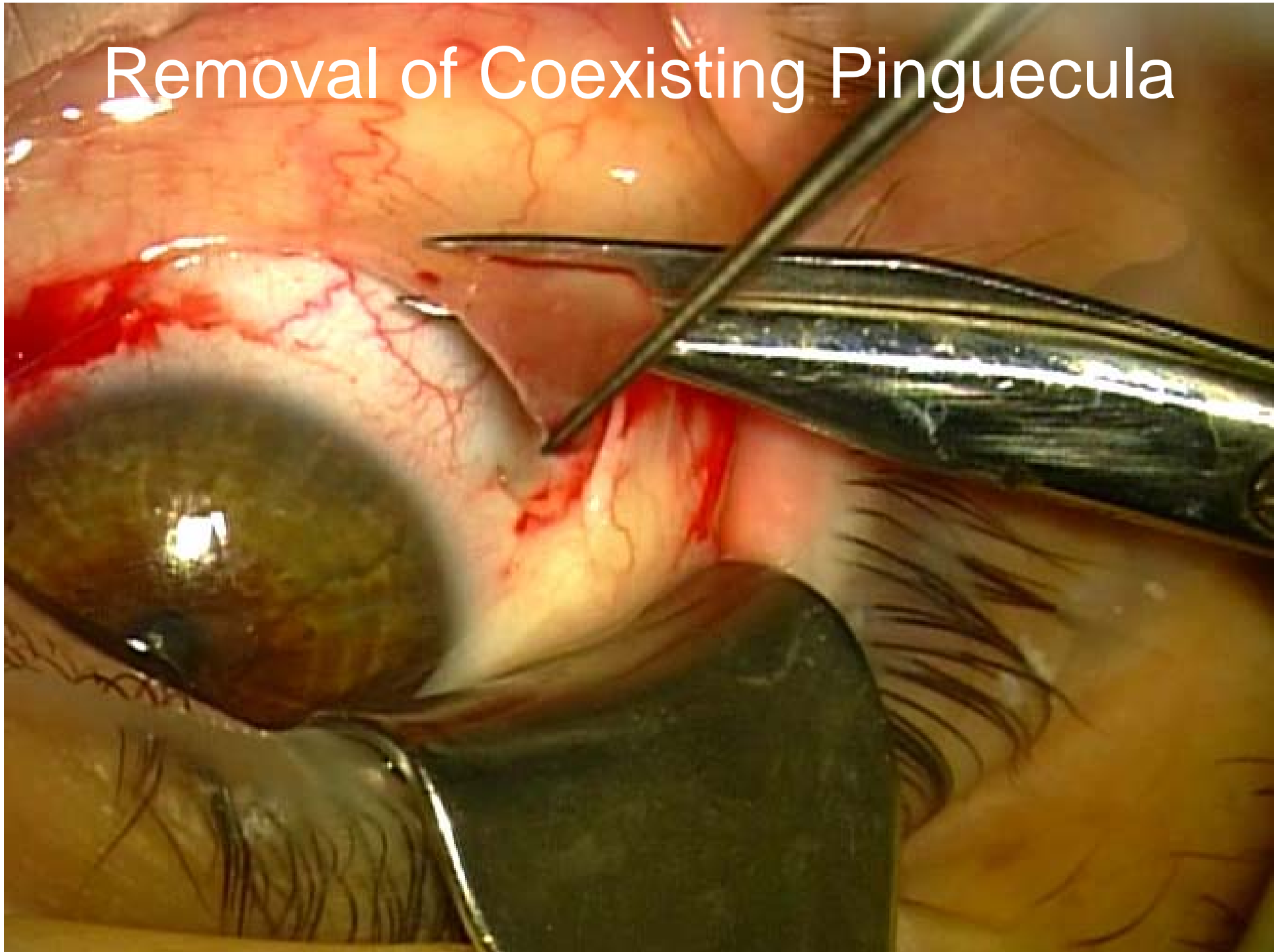
Peritomy



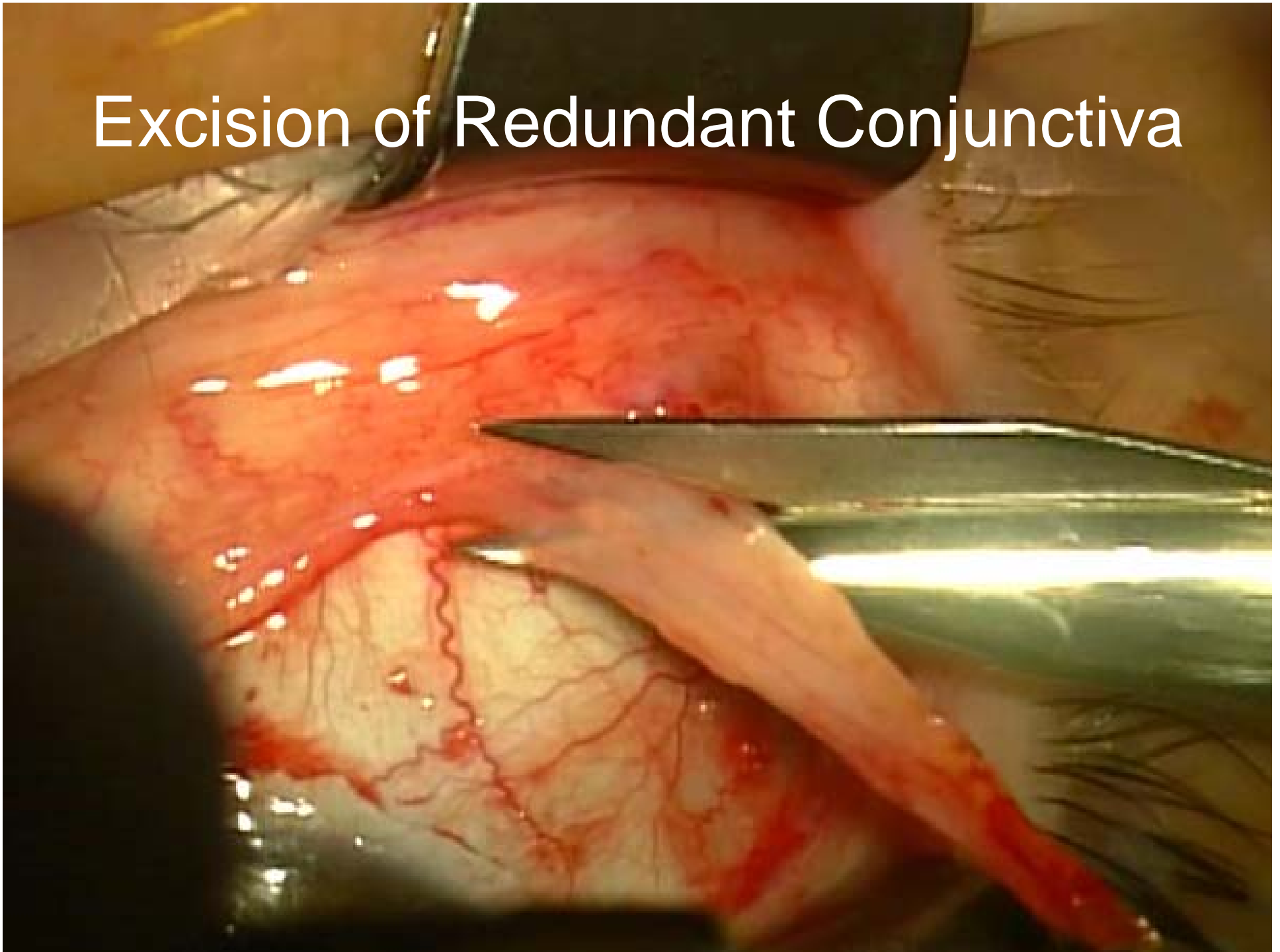
Traction suture allows the conjunctiva to recess toward the fornix



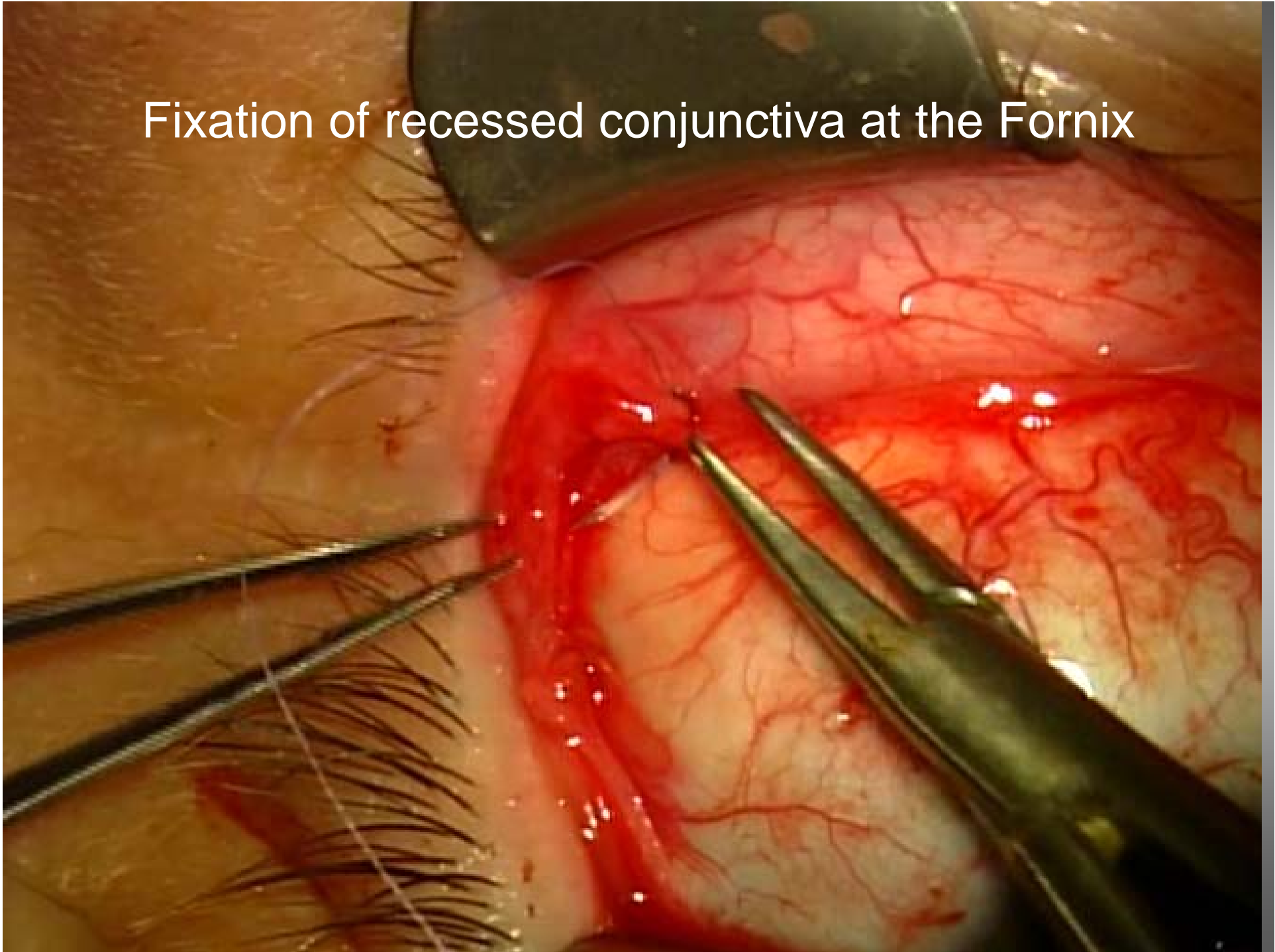
Removal of Coexisting Pinguecula



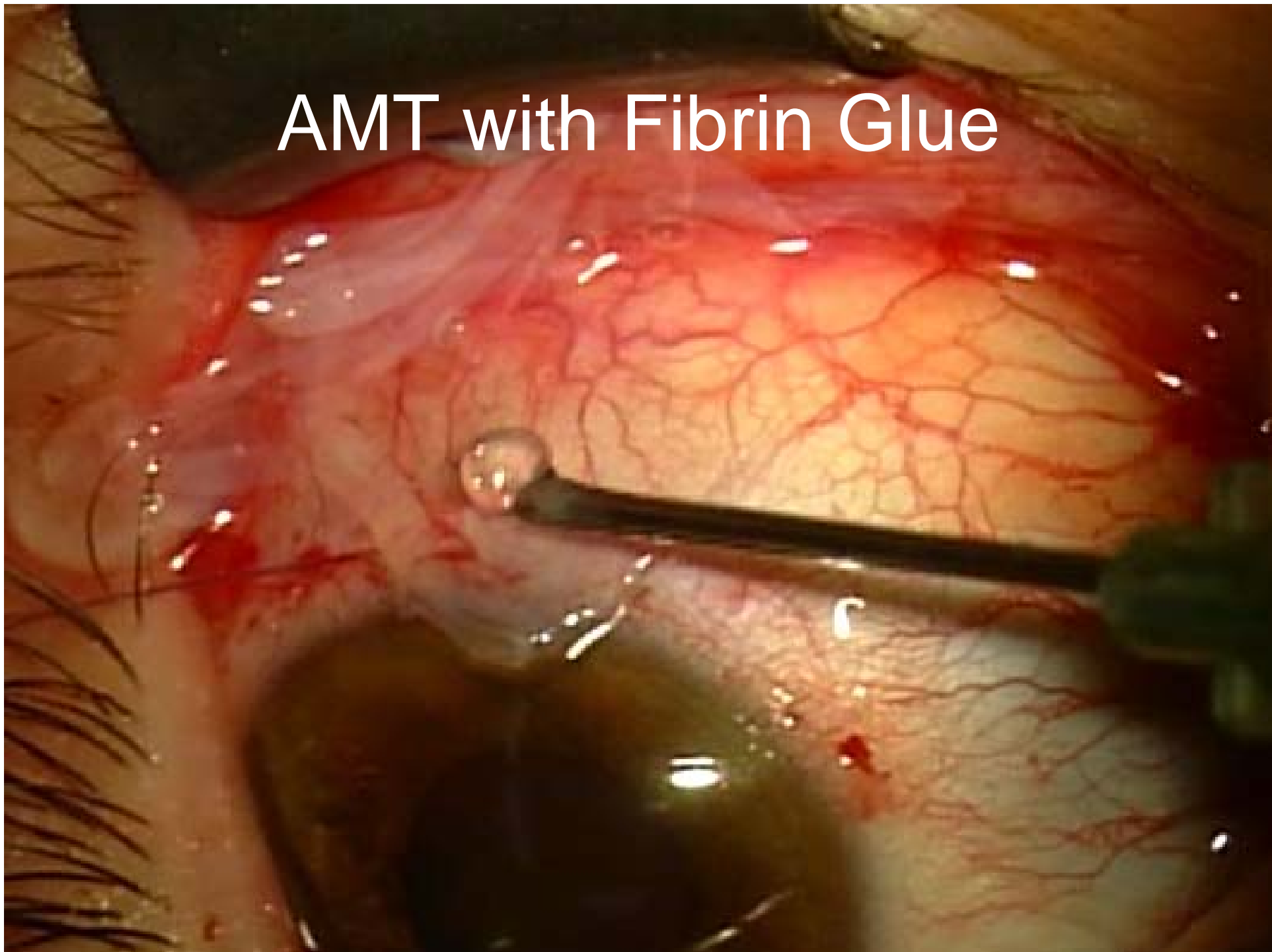
Excision of Redundant Conjunctiva



Fixation of recessed conjunctiva at the Fornix



AMT with Fibrin Glue



AMT with Fibrin Glue

