

Cryopreserved Amnion Grafts for Conjunctivochalasis and Superior Limbic Keratoconjunctivitis

By Scheffer C.G. Tseng, M.D., Ph.D. with Hosam Sheha, M.D., Ph.D.

Volume 1, Number 4

4

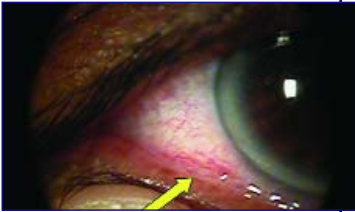


Fig. 1

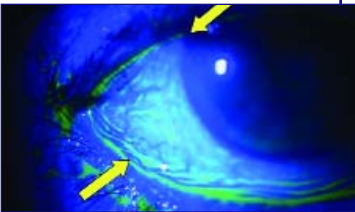


Fig. 2

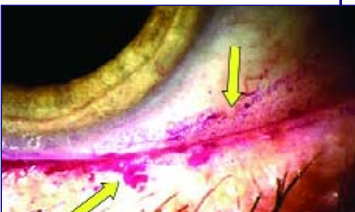

Fig. 3

Overview

Conjunctivochalasis (CCh) represents one of the most common age-related eye diseases and is characterized by the presence of redundant folds of the conjunctiva that typically are detected between the eyeball and the eyelids. It is commonly found along the lower lid margin and mechanically interferes with the normal distribution of tears giving rise to unstable tear film (dry eye) and delayed tear clearance (epiphora). The differences between CCh-induced dry eye and aqueous tear deficiency (ATD) are summarized in Table 1. For asymptomatic CCh, no treatment is needed, and patients may be given tear substitutes, lubricants, corticosteroids or antihistamine drops. Persistent symptomatic CCh despite maximal medical treatments to dry eye can be treated using amniotic membrane (AM) transplantation.

Diagnosis of Conjunctivochalasis

Slit Lamp Examination

The loose conjunctiva can be demonstrated as follows:

- Ask the patient to blink vigorously.
- Press the eyelid against the conjunctiva with an upward motion (Fig. 1).
- Fluorescein staining will help visualize the wrinkles as well as obliterate tear meniscus by the redundant conjunctival folds (Fig. 2).
- Rose Bengal staining may show punctate staining on the bulbar conjunctiva adjacent to the lid margin (Fig. 3).

Additional Information

To view additional information about conjunctivochalasis treatment and diagnosis including surgical videos visit www.osref.org

Distinguishing Feature	ATD Dry Eye	CCh Dry Eye
Symptom: Diurnal variation Worst gaze Effect of vigorous blinking Recurrent subconjunctival hemorrhage	Worse in PM Up gaze Symptom improved Infrequent	Same throughout the day Down gaze Symptom worsened Frequent
Fluorescein Staining Pattern	Low tear meniscus without interruption	Tear meniscus interruption or obliteration
Tear Clearance	Normal/Delayed	Frequently delayed
Rose Bengal Staining	Exposure zone	Non-exposure zone
Effect of Punctal Occlusion	Symptom improved	Symptom worsened

Key Surgical Steps: *Estimated surgery time: 15 min.*

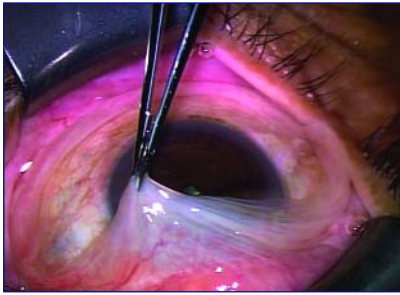


Fig. 4

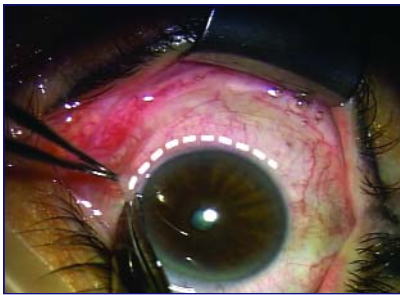

Fig. 5

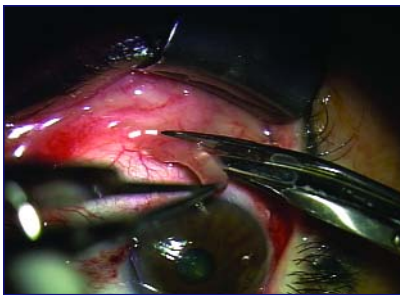

Fig. 6

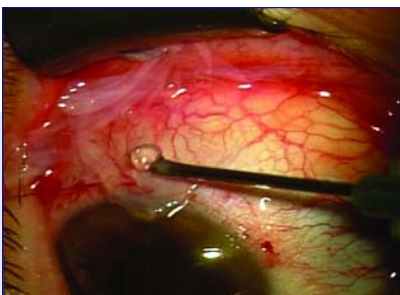

Fig. 7

Surgical Techniques for Inferior CCh:

- **Insert** a 15 mm solid blade **Speculum** (K1-5014 Katena), apply **Epinephrine** (1:1000) for hemostasis and 2% lidocaine gel (Astra Zeneca) for **Topical Anesthesia**.
- **Identify** the location of CCh by grabbing the conjunctiva with 0.12 forceps (Fig. 4).
- Create an arc like conjunctival **peritomy** from 4 to 8 o'clock positions 1-2 mm posterior to the limbus (Fig. 5).
- Place 7-0 Vicryl **Traction Suture** 1-2 mm posterior to the limbus at the 6 o'clock position. Rotate the eye upward to allow the conjunctiva posterior to the peritomy to retract and expose the bare sclera.
- **Excise** a strip of fragile and wrinkled conjunctival tissue along with any underlying movable Tenon's capsule (Fig. 6).
- **Transplant Cryopreserved Amnion Graft with Fibrin Glue:** Place the cryopreserved AmnioGraft on the bare sclera with the sticky/stromal surface facing down. Secure the membrane using fibrin glue while tucking the graft underneath the conjunctival edge and sealing the conjunctiva over the graft (Fig.7).

Supplies:

- AmnioGraft® from Bio-Tissue (1-888-296-8858):
 - AG-2015 if CCh involves the inferior temporal bulbar conjunctiva.
 - AG-2520 if CCh involves the entire inferior bulbar conjunctiva.
 - AG-3535 if CCh involves the entire inferior and superior bulbar conjunctiva.
- Traction Sutures: use 7-0 Vicryl sutures.
- For sutureless surgery: use fibrin glue; TISSEEL from Baxter Biologics (1-877-TISSEEL) 2.0 mL (Catalog # 1501236) or Evicel from Ethicon from Johnson & Johnson (1-800-255-2500) 1 mL (NDC # 63713-390-11).
- For surgery with sutures, 10-0 nylon and 7-0 Vicryl sutures are recommended.

If Associated with Pinguecula:

- **Remove** any pinguecula during the surgery to avoid progression into a pseudopterygium. AM should cover the entire denuded area (Figure 8).

If Associated with Fat Prolapse extending from the fornix (Fig. 9A):

- **Anchor** the recessed remaining conjunctival tissue to the fornix using 7-0 Vicryl mattress sutures to the sclera (Fig. 9B).

If Associated with SLK:

- Create a limbal based conjunctival flap about 5 mm posterior to the superior limbus. Rotate the eye down using a 7-0 traction suture 1-2 mm posterior to limbus at the 12 o'clock position. Remove all mobile Tenon's capsule (Fig. 10A) prior to laying down and adhering AM on the bare sclera with fibrin glue (Fig. 10B). Remove the traction suture and secure the conjunctival flap on top of AM with bipolar cautery.

Post Operative Care

Begin topical Prednisolone four times and Ocuflax three times a day for 4 weeks. Epithelialization will be completed in 2 to 3 weeks. If the surrounding conjunctiva is not inflamed, stop Ocuflax and taper off PF on a weekly schedule from four times a day. If, however, the surrounding conjunctiva is inflamed, give subconjunctival injection of 0.1 cc Kenalog (40 mg/ml) per site in the office. Symptoms related to CCh will be quickly resolved. The residual symptoms due to aqueous tear deficiency, meibomian gland dysfunction (MGD), or excessive blinking can be managed accordingly.

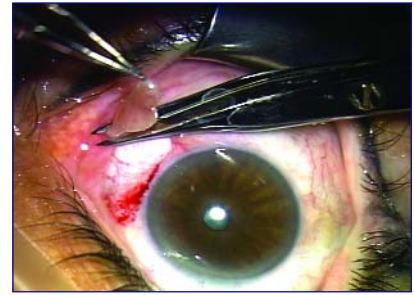


Fig. 8

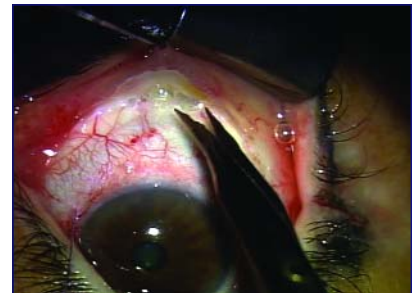


Fig. 9A

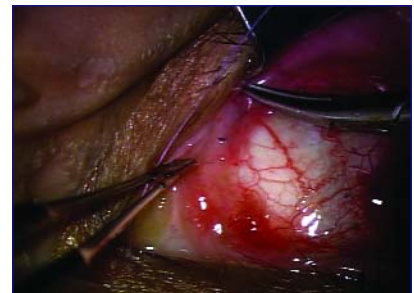


Fig. 9B

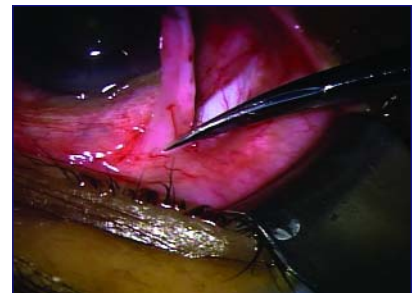


Fig. 10A

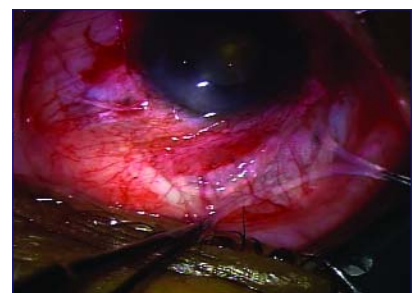

Fig. 10B

- **Why not just remove the excess conjunctiva? Why use an amnion graft?**

CCh is not caused by excessive or redundant conjunctiva. Instead it is caused by poor adhesion between the Tenon's capsule and the sclera. Simple excision may not prevent fat prolapse and may aggravate a pinguecula, if present. Covering the bare sclera with cryopreserved amniotic membrane reinforces such adhesion without stirring up unnecessary inflammation or scarring based on the important biologic actions preserved in cryopreserved amnion grafts. These include anti-inflammation, anti-scarring, anti-angiogenesis and the promotion of healing while reducing patient pain.

- **Why are cryopreserved amnion grafts recommended over other amniotic membrane products?**

AmnioGraft® is the only cryopreserved amnion graft available and approved by the FDA for commercial use in the United States. The cryopreserved method of preserving amniotic membrane is the only method for use in ocular surface wound repair and wound healing because this method retains the biologic actions of the tissue in utero (anti-scarring, anti-inflammation, anti-angiogenesis, and promotion of healing).

- **What happens if ocular irritation persists after CCh surgery?**

If the conjunctivochalasis has been corrected, the remaining irritation might come from aqueous tear deficiency dry eye, MGD blepharitis, or

delayed tear clearance, which can then be successfully treated by punctal occlusion, lid scrub, or non-preserved steroid drops.

- **Should CCh correction surgery be performed before blepharoplasty?**

Yes. If an eye had CCh and the lid is tightened through blepharoplasty, then the symptoms will get worse.

- **If the patient has entropion with CCh, should both corrective surgeries be performed at the same time?**

Operate on the entropion first to see if CCh persists. If so, then CCh will be managed accordingly.

- **Can this procedure be performed on both eyes in the same surgical session?**

Yes, because topical anesthesia makes it possible.

Provided by

The Ocular Surface Research & Education Foundation (OSREF)

To order Ocular Surface Research & Education Foundation DVD's call 1-888-296-8858

For additional clinical information, contact Scheffer C.G. Tseng, M.D., Ph.D. by phone at 305-274-1299 or by e-mail at stseng@ocularsurface.com

Financial interest disclosure: Dr Tseng and his family are >5% shareholders of TissueTech, Inc. and Bio-Tissue, Inc. which currently distributes AmnioGraft® and ProKera™.

This write up is for peer discussion purposes and the authors are not participating in commercial promotion of a product for off label use.